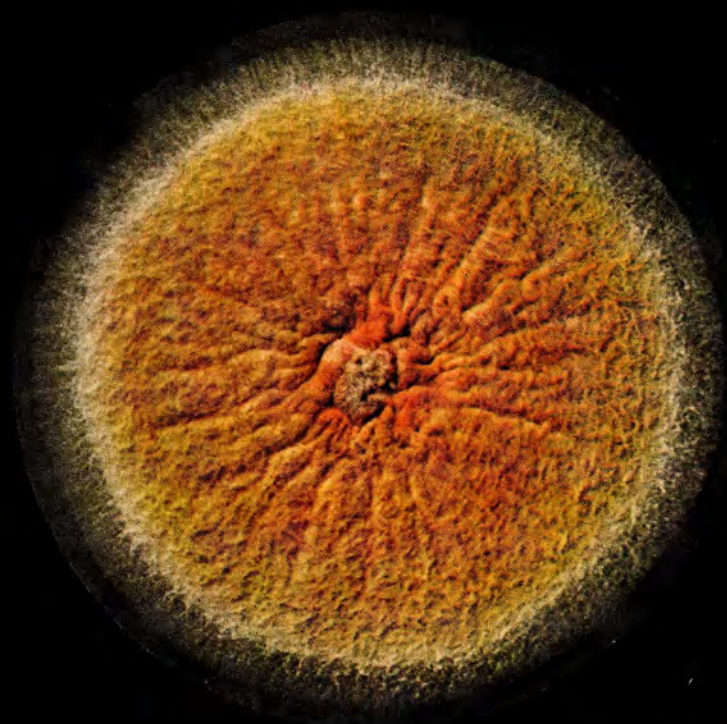


A 2547 E

# mykosen

Herausgeber und Schriftleiter: Hans Götz, Essen, Heinz Grimmer, Wiesbaden  
Detlev Hantschke, Essen, Wolf Meinhof, München, Hans Rieth, Hamburg



**8/1970**

**1. August**

Laboratory of Mycology, Dermato-venereological Center,  
Bucharest, str. Dr. Grozovici 1, Romania

## **Microsporum gypseum infection in the parrot (*Melopsittacus undulatus*)**

I. ALTERAȘ M. D. and I. COJOCARU, M. D.

The occurrence of *M. gypseum* in wild or domestic birds is rarely mentioned. GIERLOFF and KATIČ (1961), cited by DVOŘÁK and OTČENÁŠEK, reported the isolation of this species from the hen. PUGH (1965 and 1966) discovered the presence of *M. gypseum* and of *T. terrestre* only in the soil-mixed nests belonging to 12 species of birds. REES (1967) succeeded in isolating *M. gypseum* from the feathers of trapped or shot wild birds and also of fowls, together with other two keratinophilic fungi (*M. cookei* and *T. georgiae*). But no dermatophytic lesions were found by these latter authors in the respective birds. Therefore the finding of a fungal infection due to dermatophytes in a parrot seemed to us to be of interest.

### **Case history**

B. V., woman, 52 years of age, with an erythematous-vesiculous round plaque, on her left hand, 2 cm. diam., with slightly inflammatory raised borders. A smaller, but similar lesion, could be observed near the little finger of the same hand (fig. 1). The first signs

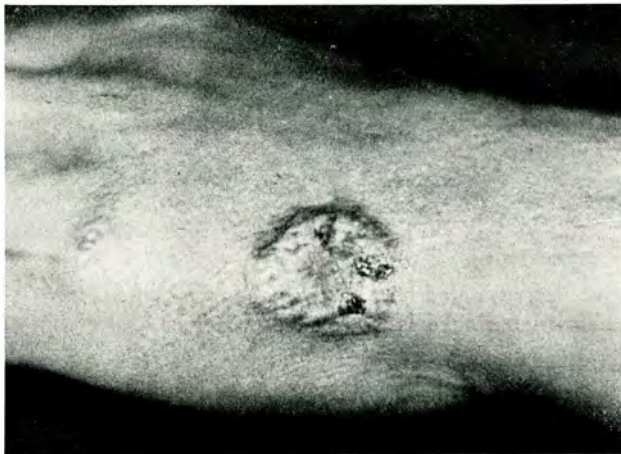

Fig. 1: Inflammatory lesion on the woman's hand

had started 2 weeks before. Microscopic examination of scrapings and vesicles showed numerous fungal elements, the culture developing pure colonies of *M. gypseum* (Bodin) Guiart & Grigoraki. Local treatment with an ointment containing Phenylhydrargyri boras<sup>\*)</sup> cured the lesions within 3 weeks.

\*) *Exomycol*®, Zyma SA, Nyon

According to the patient, she was contaminated by her parrot, kept in the house for many months. She was advised to bring the parrot for examination. The bird was sent to our laboratory, but died on the way.

It was a nice, multicoloured (green, red and blue) male parrot (*Melopsittacus undulatus*) having (on the neck, head and chest) a few scaling crusted lesions, mainly in the area around the beak, near the eyes and involving also some feathers (fig. 2). Small



Fig. 2: Scaly, crusted mycotic lesions on the parrot

alopecic patches were intermingled with hairs of abnormal appearance, which could easily be epilated. The above mentioned lesions in the parrot had an evolution of approximately 2 or 3 months

### Mycology

Direct microscopic examination of the crustlike whitish scales revealed the presence of fragmented hyphae and round spores, partly disposed like in small scutula. Invasion of hairs could hardly be distinguished. No fluorescence in Wood's light.

Transfer of scrapings and suspected hairs onto Sabouraud's glucose agar, supplemented with chloramphenicol and actidione, yielded the same agent found in the human patient, i. e. *M. gypseum*, the macroscopic and microscopical characteristics being identical in both strains.

Experimental inoculations with the isolated strains in guineapigs and human volunteers caused marked inflammatory lesions (of the herpes circinatus type), mainly in man, thus proving the high virulence of the pathogen.

## Discussion

From the data collected up to now it seems that *M. gypseum* is the most wide-spread dermatophyte (after *T. mentagrophytes*) occurring in the coat of many of wild and domestic animals, with or without signs of mycotic infection. Birds, mostly the fowls, are mainly attacked by the *Trichophyton* species, either zoophilic (*T. gallinae*, *T. mentagrophytes*, *T. verrucosum*) or even anthropophilic, sometimes (*T. schoenleini*, *T. violaceum*, etc.).

As stated by REES, geophilic dermatophytes are much less frequent in birds than in small or large wild mammals, because the majority of the formers very rarely come into contact with the soil, spending very little of their time on the ground.

To our knowledge this is the first report of a parrot being attacked by dermatophytes. It is very difficult to prove the exact origin of the fungal infection in our parrot. The agent could be picked up either from the soil (brought together with the food) or from an animal (cat or dog) or even from the air. The most plausible contamination remains however the soil, because no animal was kept in the house and the mode of air transmission is generally hardly accepted (in spite of a few positive findings). The only question remaining to be cleared up is whether *M. gypseum*, harboured as a saprophyte in the feathers of the parrot, has not found some special circumstances for becoming extremely virulent?

## Summary

A case of mycotic infection by *M. gypseum* in a parrot (*Melopsittacus undulatus*) is reported here. Alopecic, scaly lesions were found around the beak and eyes, the feathers being poorly involved. The disease had been transmitted into a female, who developed inflammatory herpes circinatus on her hand. The organism isolated, the same in both cases, manifested a high virulence in experimental inoculations in animals and humans. The occurrence of common dermatophytes and other keratinophilic fungi in birds is discussed.

## Zusammenfassung

Bericht über einen Fall von Pilzinfektion durch *Microsporium gypseum* bei einem Wellensittich (*Melopsittacus undulatus*). Rund um den Schnabel und um die Augen herum fanden sich schuppende Alopecieherde; die Federn waren nur wenig befallen. Die Krankheit wurde auf eine 52jährige Frau übertragen, bei der sich an der Kleinfingerseite des linken Handrückens ein entzündlicher Herpes circinatus entwickelte. In beiden Fällen wurde der gleiche Organismus isoliert; er erwies sich als hochvirulent nach experimentellen Inokulationen bei Meerschweinchen und bei freiwilligen Versuchspersonen. In der Diskussion wird auf das Vorkommen von Dermatophyten und anderen keratinophilen Pilzen bei Vögeln hingewiesen. Bei Wellensittichen ist dies der erste Bericht über eine Erkrankung durch Dermatophyten.

## References

1. DVOŘÁK, I. & OTČENÁŠEK, M.: Geophilic, zoophilic and anthropophilic dermatophytes. *Mycopathol. et Mycol. appl.* **23**, 4, 294—296 (1964).
2. PUGH, G. J. F.: Cellulolytic and keratinophilic fungi recorded on birds *Sabouraudia* **4**, 85—91 (1965).
3. PUGH, G. J. F.: Associations between birds-nests, their pH and keratinophilic fungi. *Sabouraudia* **5**, 49—53 (1966).
4. REES, R. G.: Keratinophilic fungi from Queensland. II. Isolations from feathers of wild birds. *Sabouraudia* **6**, 14—18 (1967).
5. REES, R. G.: Keratinophilic fungi from Queensland. III. Isolations from feathers of domestic fowls. *Sabouraudia* **6**, 19—28 (1967 b).

Authors' address: Centrul Dermato-venerologic, str. Dr. Grozovici nr. 1, București 10, Romania